

Minimally invasive suture suspension of the brow

Steven H. Dayan, MD, FACS

Benjamin A. Bassichis, MD

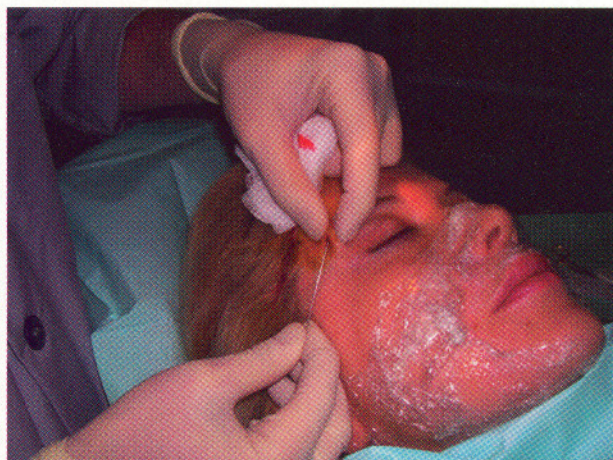


Figure 1. The Keith needle is placed in the lateral superior brow incision.

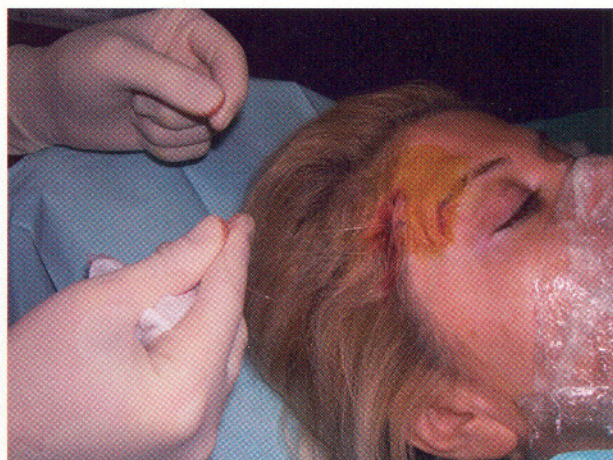

Figure 2. The Mersilene suture is pulled through to the medial superior brow exit site.

The technique we describe—suture suspension—is a modification of methods that have been described in the past; this modification results in better outcomes.^{1,2} Suture suspension is a minimally invasive technique that provides a noticeable, more permanent elevation of the temporal brow.³

As is the case before any cosmetic surgical procedure, the surgeon first performs a careful analysis of the patient's facial features. Next, the planned sites of suture suspension are measured, and the anterior and temporal hairline is examined for acceptable areas.

After surgery has been planned, the surgical area is sterilized with an antiseptic solution, and the incision sites and the temporal forehead are injected with lidocaine with epinephrine for pain control and hemostasis. At each suture suspension site, the surgeon makes four 5- to 7-mm stab

incisions—two in the superior portion of the brow and two in the hairline. At the brow, dissecting scissors and a small two-prong hook are used to elevate the subdermal level superiorly by 5 or 6 mm. This elevation appears to minimize the potential wrinkling and pulling of the skin. Next, the stab incisions are made in the temporal hairline. A Keith needle is then placed into the lateral superior brow incision, and it is passed until it exits into the medial brow incision (figure 1). A 4-0 Mersilene suture is attached to the needle and pulled through to the medial superior brow exit site (figure 2). The Keith needle is then placed into the lateral superior brow incision and pushed into the subdermal plexus through the forehead up to the lateral hairline incision. After both ends of the suture end up in the medial or lateral hairline incision, the patient's head is raised so that the patient and the surgeon can gauge

From the Division of Facial Plastic Surgery, Department of Otolaryngology–Head and Neck Surgery, University of Illinois at Chicago (Dr. Dayan), and from the Advanced Facial Plastic Surgery Center, Dallas, and the Division of Facial Plastic Surgery, Department of Otolaryngology–Head and Neck Surgery, University of Texas Southwestern Medical Center, Dallas (Dr. Bassichis).

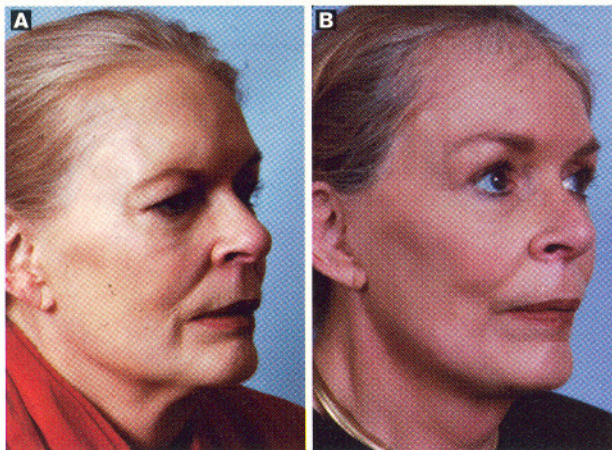


Figure 3. Pre- (A) and postoperative (B) photographs document the improvement in the appearance of the lateral brow.

how much to alter the brow position. The suture is then secured, and the small incisions are closed with nonreactive suture material.

Rejuvenation of the upper third of the face gives many patients a more youthful appearance (figure 3). Suture suspension techniques have been used for years, but they never gained full acceptance. However, a new emphasis on achieving more long-lasting results with minimal downtime has led us to revisit suture suspension techniques.

References

1. Erol OO, Sozer SO, Velidedeoglu HV. Brow suspension, a minimally invasive technique in facial rejuvenation. *Plast Reconstr Surg* 2002;109:2521-32.
2. Giampapa VC, DiBernardi BE. Neck recontouring with suture suspension and liposuction: An alternative for the early rhytidectomy candidate. *Aesth Plast Surg* 1995;19:217-23.
3. Dayan SH, Bassichis BA. The puppet facelift: Minimally invasive facelift techniques. *Cosmetic Dermatology* 2003;16:53-60.